

Evaluation of the Image Quality of Ultra-Low-Dose Paranasal Sinus CT

Melih Akşamoğlu¹, Mehmet Sait Menzilcioğlu¹

¹ Department of Radiology, Gaziantep University Faculty of Medicine, Gaziantep, Turkey

ABSTRACT

Objective: We aimed to investigate the image quality of paranasal sinus computed tomography (CT) scans obtained with the “Advanced intelligent Clear-IQ Engine” (AiCE) software and ultra-low dose parameters in patients with pre-diagnosed rhinitis, sinusitis or nasal septum deviation.

Methods: The first 50 patients (31 men and 19 women, aged 18-70 years) who agreed to participate in our prospectively planned study were included in the study. Imaging of the patients was performed with a 160-slice multidetector CT device Canon Aquilion Prime SP (Canon Medical Systems, Otawara, Japan). Tube voltage of 80 kV and tube current of 40 mA were chosen. The effective radiation dose (ED) was calculated based on the “dose-length product” (DLP) information of each patient. Evaluation of images was made on reformat images made with “AiCE Bone” filter in the axial and coronal planes. All images were double-blindly evaluated by 2 radiologists out of 5 points (5 = very good; 1 = not diagnostic). The visibility of 17 bilateral important anatomical landmarks examined on paranasal sinus CT was scored (0 = not visible; 2 = completely visible). In the evaluation of images, the agreement between radiologists was evaluated with Kappa statistics.

Results: The median ED value of the CT protocol was 0.015 ± 0.001 mSv [range 0.012-0.017 mSv]. The overall image quality of the images in our study was interpreted as 4 (good) or 3 (moderate) for all patients. Inter-research agreement was 92%. Most of the anatomical landmarks evaluated were completely visible. Six (bilateral of three) anatomical landmarks could be partially visible in some patients.

Conclusion: Combining the ultra-low dose CT protocol and the AiCE reconstruction algorithm makes it possible to achieve very low ED values in paranasal sinus CT scans and still obtain sufficient image quality in indications such as septum deviation and sinusitis.

Keywords: Multidetector Computed Tomography; Paranasal Sinus; Radiation Exposure

INTRODUCTION

Computed Tomography (CT) is a diagnostic method that is widely used in the radiological diagnosis of many diseases and uses ionizing radiation. With the increasing use of CT, the exposure of people to ionizing radiation is constantly increasing. Ionizing radiation damages cells and tissues, disrupts the structure of genetic material and increases the risk of cancer in the long term [1]. For these reasons, techniques to reduce the radiation dose used in CT are constantly being developed.

CT is widely used for diagnostic purposes in almost all body imaging. It is also the gold standard for the evaluation of the paranasal sinus cavities and facial bones for most indications [2]. It provides important information about surgically important anatomical details, variations, soft tissues and bone structures, especially in the management of sinus inflammation [3]. In paranasal sinus CT, the presence of organs that are more sensitive

to radiation, such as eye lens and thyroid, near the scanning area makes the radiation dose in this scan even more important [4]. The fact that the scanning is mostly done with young people and in some cases the need for follow-up imaging makes the issue even more serious. For these reasons, protocols containing as low radiation dose as possible should be arranged in every hospital.

In parallel with technological developments, advanced iterative dose reduction methods are applied in current CT devices. One of the most up-to-date among these is the “Advanced intelligent Clear-IQ Engine” (AiCE) dose reduction technology. In our study, we aimed to investigate the image quality of paranasal sinus CT scan obtained with AiCE software and ultra-low dose parameters in patients with prediagnosed rhinitis, sinusitis or nasal septum deviation.

How to cite: Akşamoğlu M and Menzilcioğlu MS (2023) Evaluation of the Image Quality of Ultra-Low-Dose Paranasal Sinus CT. Eur J Ther. 29(2):143-148. <https://doi.org/10.58600/eurjther.20232902-1131.y>

Corresponding Author: Melih Akşamoğlu E-mail: draksamoglu@gmail.com

Received: 08.05.2023 • **Accepted:** 30.05.2023 • **Published Online:** 02.06.2023

METHODS

The first 50 patients admitted to our radiology department between November 2019 and September 2022, and agreed to participate in our prospectively planned study were included in the study. Patients with a pre-diagnosis of rhinitis, sinusitis or septum deviation were determined as inclusion criteria. Patients under the age of 18 and those with a history of craniofacial trauma were not included in the study. Patients who moved during the scanning were excluded from the study.

Our study included 31 male and 19 female patients aged 18-70 years. Imaging of the patients was performed with a 160-slice multidetector CT device, Canon Aquilion Prime SP (Canon Medical Systems, Otawara, Japan). The settings were used as follows; tube voltage: 80 kV; rotation time: 0.35 s; tube current: 40 mA (14 mAs); collimation: 80x0.5 mm; pitch: 1.388. The patients were in the supine position and their images were taken in the axial plane. The scanning area was chosen from the roof of the frontal sinus to the end of the maxilla. Evaluation was made on reformat images with a section thickness of 2 mm made with "AiCE Bone" filter in the axial and coronal planes.

Volume CT dose index (CTDIvol) and dose-length product (DLP) of each patient were recorded. For the calculation of the effective radiation dose (ED), the product of the constant coefficient of 0.0023 mSv/(mGy.cm) recommended by the European Working Group for facial bones and the DLP value was used [5].

All images were evaluated double-blindly by 2 radiologists with 13 years and 11 years of experience, respectively. Initially, overall diagnostic image quality was scored out of 5 points (5=very good; 4 = good; 3 = moderate; 2 = low; 1 = not diagnostic). Then, the visibility of the borders of the nasal septum, bone septa of ethmoid cells, uncinat process of ethmoid bone, maxillary sinus ostium, ethmoid infundibulum, nasolacrimal duct, fovea ethmoidalis, cribriform plate and lamina papyracea were scored for each patient (Figure 1). The scoring system used for this was as follows; 0 (not visible), 1 (partially visible), or 2 (completely visible). Except for the nasal septum, other anatomical structures were evaluated separately for the right and left. The scores of the anatomical structures were recorded separately by both radiologists.

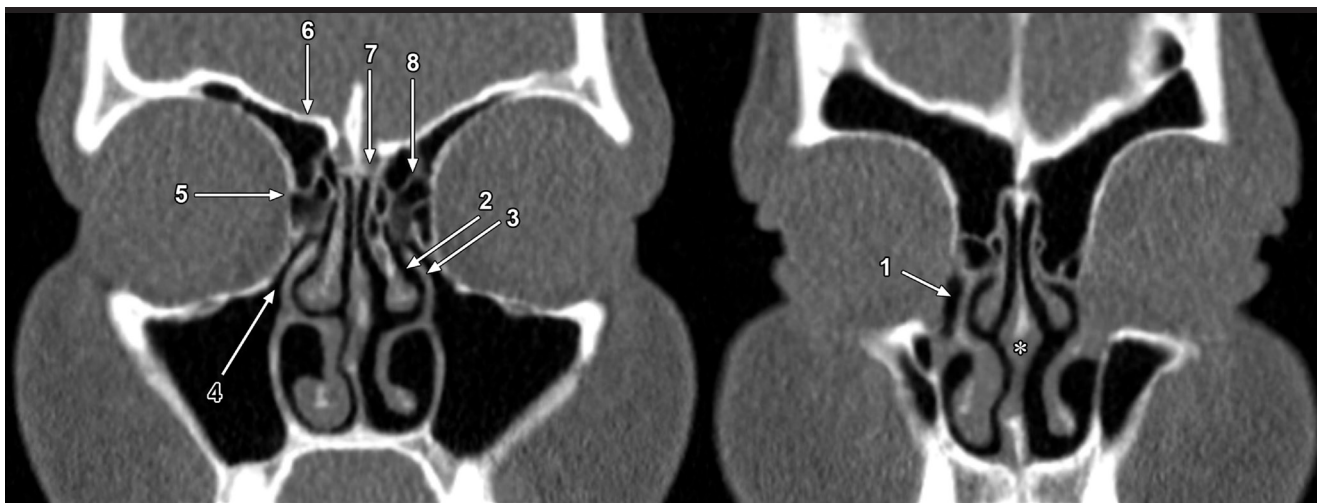


Figure 1. Anatomical structures scored. 1: nasolacrimal duct; 2: ethmoid infundibulum; 3: uncinat process of ethmoid bone; 4: maxillary sinus ostium; 5: lamina papyracea; 6: fovea ethmoidalis; 7: cribriform plate; 8: ethmoid cells; * nasal septum

Main Points:

- The most important disadvantage of CT is that it uses ionizing radiation.
- Image quality is the most important limiting factor in reducing the radiation dose in CT protocols.
- In paranasal sinus CT scans performed with AiCE, a contemporary dose reduction algorithm, it is possible to achieve sufficient image quality in pre-diagnoses such as rhinitis, sinusitis and septum deviation, even at very low doses.

Statistical Analysis

Descriptive statistics of the data obtained from the study were given with mean, standard deviation for numerical variables, and frequency and percentage analysis for categorical variables. In the evaluation of images, the agreement between 2 different radiologists was evaluated with Kappa statistics. Analyzes were performed with the IBM SPSS Statistics for Windows, version 22.0 (IBM Corp., Armonk, New York, United States) and $p < 0.05$ was chosen as the significance level.

Power Analysis: The total number of patients required for a moderate agreement ($r=0.5$) between the scores given by 2 different radiologists to the image quality of the images to be obtained by CT was determined as 29 ($\alpha=0.05$, $1-\beta=0.80$). Analysis was done in Gpower version 3.1.

RESULTS

A total of 50 patients, 31 male (62%) and 19 female (38%), were included in the study. The mean age of the patients was 30 and the age range was 18-70.

The CTDIvol value of the applied protocol was 0.40 mGy. The median DLP value was 6.5±0.5 mGy.cm [range 5.20-7.50 mGy.cm], and the calculated median ED was 0.015±0.001 mSv [range 0.012-0.017 mSv].

The overall image quality of the images in our study was interpreted as 4 (good) or 3 (moderate) for all patients (Figure 2). There were no patients whose image quality was interpreted as 5 (very good), 2 (low), or 1 (not diagnostic). The agreement between radiologists was 92% (Table 1). Nasal septum, bony septa of ethmoid cells, uncinete process of ethmoid bone, maxillary sinus ostium, ethmoid infundibulum and nasolacrimal duct borders were completely visible in all patients. The borders of one or more of the fovea ethmoidalis, cribriform plate and lamina papyracea structures were partially visible in some patients (Figure 3). There was no patient in whom the borders of these structures were not visible at all (Table 2).

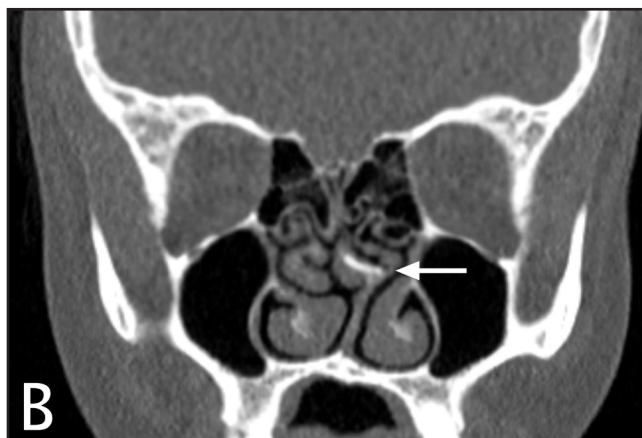

Figure 2. General image quality: Images of 2 different patients whose image quality was interpreted as “good” (A) and moderate (B) by both radiologists. Although the image quality and clarity are different, septum deviation and bone spur formation (arrows) can be easily evaluated in both patients.

Table 1. Evaluation of the images in terms of overall image quality

| | Number of Patients | |
|--------------------------|--------------------|---------------|
| | Radiologist 1 | Radiologist 2 |
| Scoring of image quality | | |
| 1: Not diagnostic | 0 | 0 |
| 2: Low | 0 | 0 |
| 3: Moderate | 25 | 27 |
| 4: Good | 25 | 23 |
| 5: Very good | 0 | 0 |
| Agreement | %92 | |
| Reliability | κ =0.84 | |

κ: Kappa value

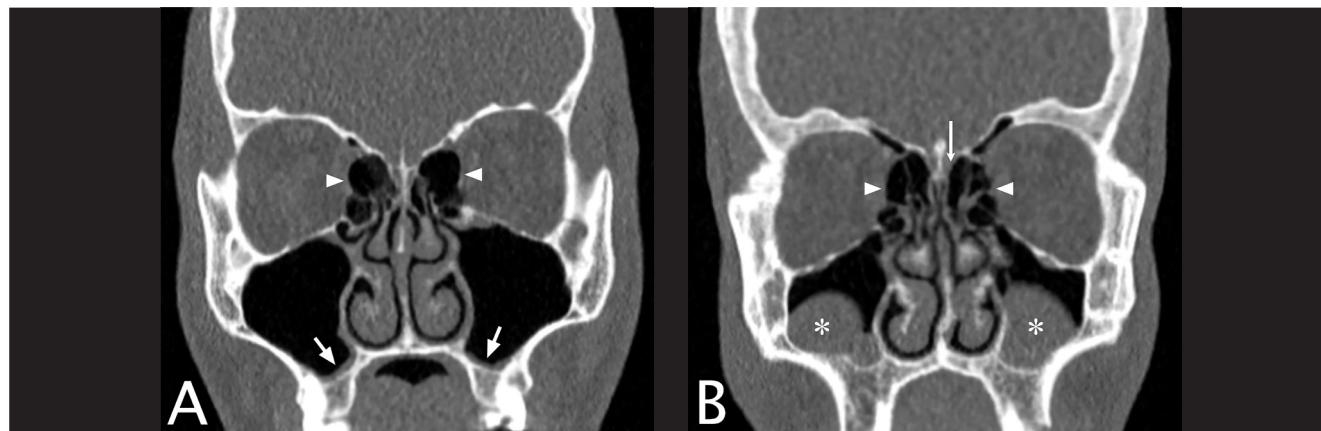


Figure 3. Examples of partially visible anatomical structures: **A)** A patient whose image quality was interpreted as “good” by both radiologists. Minimal mucosal thickening (arrows) is observed in the bilateral maxillary sinus. In this patient, both radiologists evaluated that the bilateral lamina papyracea (arrowheads) were partially visible. **B)** A patient whose image quality was interpreted as “moderate” by both radiologists. Retention cysts (asterisks) are observed in the bilateral maxillary sinus. In this patient, both radiologists evaluated that the borders of the bilateral lamina papyracea (arrowheads) and the left cribriform plateau (arrow) were partially visible.

Table 2. Evaluation of the visibility of anatomical structures

| | NS | | Ethmoid Cells | | | | Uncinate Process | | | | Maxillary Ostium | | | | Ethmoid Infundibulum | | | | Nasolacrimal Duct | | | | Fovea Ethmoidalis | | | | Cribriform Plate | | | | Lamina Papyracea | | | |
|---------------|-----|----|---------------|----|-----|----|------------------|----|-----|----|------------------|----|-----|----|----------------------|----|-----|----|-------------------|----|-------|----|-------------------|----|------|----|------------------|----|-------|----|------------------|----|----|----|
| | | | R | | L | | R | | L | | R | | L | | R | | L | | R | | L | | R | | L | | R | | L | | | | | |
| | R1 | R2 | R1 | R2 | R1 | R2 | R1 | R2 | R1 | R2 | R1 | R2 | R1 | R2 | R1 | R2 | R1 | R2 | R1 | R2 | R1 | R2 | R1 | R2 | R1 | R2 | R1 | R2 | R1 | R2 | | | | |
| 0: NV | 0 | 0 | 0 | 0 | 0 | 0 | 0 | 0 | 0 | 0 | 0 | 0 | 0 | 0 | 0 | 0 | 0 | 0 | 0 | 0 | 0 | 0 | 0 | 0 | 0 | 0 | 0 | 0 | 0 | 0 | 0 | | | |
| 1: PV | 0 | 0 | 0 | 0 | 0 | 0 | 0 | 0 | 0 | 0 | 0 | 0 | 0 | 0 | 0 | 0 | 0 | 0 | 0 | 0 | 0 | 0 | 6 | 7 | 3 | 5 | 12 | 17 | 13 | 16 | 21 | 24 | 20 | 24 |
| 2: CV | 50 | 50 | 50 | 50 | 50 | 50 | 50 | 50 | 50 | 50 | 50 | 50 | 50 | 50 | 50 | 50 | 50 | 50 | 50 | 50 | 50 | 44 | 43 | 47 | 45 | 38 | 33 | 37 | 34 | 29 | 26 | 30 | 26 | |
| <u>Ag (%)</u> | 100 | | 100 | | 100 | | 100 | | 100 | | 100 | | 100 | | 100 | | 100 | | 100 | | 98 | | 96 | | 90 | | 94 | | 94 | | 92 | | | |
| Reli * | 1 | | 1 | | 1 | | 1 | | 1 | | 1 | | 1 | | 1 | | 1 | | 1 | | 0.912 | | 0.73 | | 0.76 | | 0.855 | | 0.879 | | 0.839 | | | |

R: Right; L: Left; R1: Radiologist1; R2: Radiologist2; NV: Not visible; PV: Partially visible; CV: Completely visible; NS: Nasal Septum; Ag: Agreement; Reli: Reliability* The reliability line shows the calculated kappa value (κ).

DISCUSSION

The CTDIvol value of the protocol in our study (tube voltage: 80 kV; tube current: 14 mAs; rotation time: 0.35 s; pitch value: 1.388 and AiCE reconstruction algorithm) is 0.4 mGy. The same value in the protocol we use in routine paranasal sinus CT scans with the same device in our hospital (tube voltage: 100 kV; tube current: 75 mAs; rotation time: 0.5 s; pitch value: 1.388 and AiCE reconstruction algorithm) is 4.0 mGy. Thus, with the parameters we used in the study protocol, we achieved a 90% dose reduction compared to our routine daily practice. The ED values in our study are in the range of 0.012-0.017 mSv. In a study, the mean ED value was found to be 0.0398 mSv in paranasal sinus radiographs [6]. So, the ED values we obtained are even below the radiographic ED value.

The overall image quality of our study protocol was not excellent, but was quite good according to the results of the evaluation by both radiologists with high agreement. We believe that with the AiCE reconstruction algorithm and the parameters we have chosen, adequate image quality can be obtained for indications such as evaluation of septum deviation and sinusitis detection in paranasal sinus CT scans, despite very low ED values. To date, different methods such as low tube voltage, low tube current-time value, high pitch value and iterative dose reduction methods have been tried to reduce ionizing radiation exposure in paranasal sinus CT scans, and the most important parameter limiting the use of these methods is image quality [7-11]. There are other studies in the literature combining iterative dose reduction method and low dose scanning protocol. In a study performed with Adaptive Iterative Dose Reduction 3 Dimensional (AIDR 3D) on the Toshiba Aquilion Prime device, the mean DLP value was found to be 33.12 ± 4.53 and the mean ED value was 0.08 ± 0.07 mSv [12]. Although the ED values we obtained in our study were lower than in this study, no serious problems were encountered in the distinguishability of anatomical structures. In another study performed with the Siemens Somatom Force device and ADMIRE reconstruction, the median ED value was calculated as 0.012 mSv, and it was stated that acute inflammatory sinus diseases can be reliably excluded with these images [2]. The ED values obtained in our study are similar to these values. Since our study was not planned only for patients with a prediagnosis of sinusitis, the detection rate of sinusitis was not investigated. However, no difficulties were encountered in the evaluation of the sinus cavities in terms of inflammation or mucosal thickening in our patients. Similarly, septum borders, deviation and bone spur formation, if any, could be easily observed.

The most important perhaps the only significant weakness in the image quality of the patients included in our study was the incomplete demarcation of thin bone structures. This situation was encountered especially in the evaluation of the cribriform plate and lamina papyracea, and sometimes in the fovea ethmoidalis. Of course, in patients with a prediagnosis of septum deviation, this situation cannot be expected to have a negative effect on the diagnosis. However, we think that the integrity of these bones cannot be adequately evaluated in paranasal sinus masses that thin or erode the sinonasal bone structures and

require malignant/benign distinction, and this method may also be insufficient in the evaluation of trauma.

Limitations

There were some limitations in our study. First, the quality assessment in our study was subjective and there was no numerical criterion. However, we thought that this would not pose a serious problem due to the high agreement between researchers. Secondly, the image quality of a fixed protocol was investigated in our study and no comparison was made with the standard scanning protocol, different parameters, or different device. Finally, CT scans for a limited number of indications were included in our study, and the effectiveness of the method in patients with suspected malignancy was not investigated. Therefore, evaluations were made only through the bone window and the image quality of the soft tissue filter was not investigated.

CONCLUSION

Combining the ultra-low-dose acquisition protocol with the AiCE reconstruction algorithm makes it possible to achieve very low ED values in paranasal sinus CT scans and still obtain sufficient image quality in indications such as septum deviation and sinusitis.

Peer-review: Externally peer-reviewed.

Support Information: This study was supported by Gaziantep University Scientific Research Projects Unit (TF.ALT.19.38).

Acknowledgments: We sincerely thank the Gaziantep University Research Projects Unit for their support. Also we would like to thank Dr. İlkay Doğan for his valuable assistance in statistical calculations.

Conflict of interest: The authors have no conflicts of interest to declare.

Authors' Contributions: M.A. designed the study, researched the literature, and wrote the article; M.A., M.S.M. evaluated the image quality and edited the paper. All authors read and approved the final version.

Ethics Committee Approval: This study was approved by Gaziantep University Medical School Medical Ethics Committee with the decision numbered 2019/241 (Date: 22 May 2019, Protocol Number: 241) and supported by Gaziantep University Scientific Research Projects Unit (TF.ALT.19.38).

REFERENCES

- 1- Desouky O, Ding N, Zhou G. (2015) Targeted and non-targeted effects of ionizing radiation. *J Radiat Res Appl Sci.* 8(2):247-54. <https://doi.org/10.1016/j.jrras.2015.03.003>
- 2- Petritsch B, Kosmala A, Weng AM, Bley TA (2019) Tin-filtered 100 kV ultra-low-dose CT of the paranasal sinus: Initial clinical results. *PLoS One.* 14(5):e0216295. <https://doi.org/10.1371/journal.pone.0216295>

- 3- O'Brien Sr WT, Hamelin S, Weitzel EK (2016) The preoperative sinus CT: avoiding a "CLOSE" call with surgical complications. *Radiology*. 281(1):10-21. <https://doi.org/10.1148/radiol.2016152230>
- 4- Diklić A, Zujic PV, Šegota D, Debeljuh DD, Jurković S, Brambilla M, Kalra MK (2020) Optimization of paranasal sinus CT procedure: Ultra-low dose CT as a roadmap for pre-functional endoscopic sinus surgery. *Phys Med*. 78:195-200. <https://doi.org/10.1016/j.ejmp.2020.09.014>
- 5- Bongartz G. European guidelines on quality criteria for computed tomography: 1999.
- 6- Chaparian A, Tavakoli I, Karimi V (2013) Organ doses, effective dose, and radiation risk assessment in radiography of pediatric paranasal sinuses (Waters view). *Asian Biomed*. 7(5):695-8. <https://doi.org/10.5372/1905-7415.0705.228>
- 7- Bodelle B, Wichmann JL, Klotz N, Lehnert T, Vogl TJ, Luboldt W, Schulz B (2015) Seventy kilovolt ultra-low dose CT of the paranasal sinus: first clinical results. *Clin Radiol*. 70(7):711-5. <https://doi.org/10.1016/j.crad.2015.03.002>
- 8- Kearney SE, Jones P, Meakin K, Garvey CJ (1997) CT scanning of the paranasal sinuses--the effect of reducing mAs. *Br J Radiol*. 70(838):1071-4. <https://doi.org/10.1259/bjr.70.838.9404216>
- 9- Brem MH, Zamani AA, Riva R, Zou KH, Rumboldt Z, Hennig FF, Kikinis R, Norbash AM, Schoepf UJ (2007) Multidetector CT of the paranasal sinus: potential for radiation dose reduction. *Radiology*. 243(3):847-52. <https://doi.org/10.1148/radiol.2433050207>
- 10- Bulla S, Blanke P, Hassepas F, Krauss T, Winterer JT, Breunig C, Langer M, Pache G (2012) Reducing the radiation dose for low-dose CT of the paranasal sinuses using iterative reconstruction: feasibility and image quality. *Eur J Radiol*. 81(9):2246-50. <https://doi.org/10.1016/j.ejrad.2011.05.002>
- 11- Aksoy EA, Özden SU, Karaarslan E, Ünal ÖF, Tanyeri H (2014) Reliability of high-pitch ultra-low-dose paranasal sinus computed tomography for evaluating paranasal sinus anatomy and sinus disease. *J Craniofac Surg*. 25(5):1801-4. <https://doi.org/10.1097/scs.0000000000000966>
- 12- Schaafs LA, Lenk J, Hamm B, Niehues SM (2016) Reducing the dose of CT of the paranasal sinuses: potential of an iterative reconstruction algorithm. *Dentomaxillofac Radiol*. 45(7):20160127. <https://doi.org/10.1259/dmfr.20160127>