

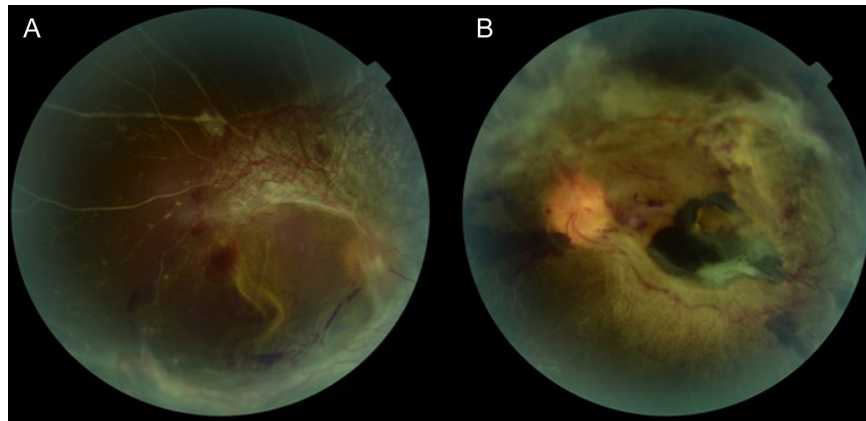
Advanced Proliferative Diabetic Retinopathy

Mücella Arıkan Yorgun

Department of Ophthalmology, Yıldırım Beyazıt University, Ankara, Turkey

Color fundus photograph of a 31-year-old man with type 1 diabetes. Best-corrected visual acuity was 20/100 in each eye. Note the extensive fibrovascular proliferation, ghost vessels, macular dragging, preretinal hemorrhages, and tractional retinal detachment (A: right eye and B: left eye).

Keywords: Advanced proliferative diabetic retinopathy, diabetes mellitus, proliferative diabetic retinopathy, tractional retinal detachment



Cite this article as: Arıkan Yorgun M. Advanced proliferative diabetic retinopathy *Eur J Ther.* 2022;28(1):81.

Corresponding author: Mücella Arıkan Yorgun, e-mail: mcllarkn@yahoo.com

Received: December 4, 2021 **Accepted:** February 1, 2022



Copyright@Author(s) – Available online at eurjther.com.

Content of this journal is licensed under a Creative Commons Attribution-NonCommercial 4.0 International License.